

# Burned-Out Testicular Tumour: An Unusual Presentation

## *Burned-Out de Tumor Testicular: Uma Apresentação Incomum*

Nuno Santos Sousa<sup>1</sup>; Duarte Santos-Sousa<sup>2</sup>; Rafaela Miranda<sup>3</sup>;  
Andreia Coutada<sup>4</sup>; Mariana Afonso<sup>2</sup>; Simão Costa Martins<sup>2</sup>

**Corresponding Author/Autor Correspondente:**

Nuno Santos Sousa [nunosantossousa@outlook.com]

ORCID: <https://orcid.org/0000-0001-6921-1680>

Unidade de Saúde Familiar Citânia,

Unidade Local de Saúde Tâmega e Sousa, Porto, Portugal

Rua Rainha D. Leonor, 107, 4590-612 Paços de Ferreira

DOI: <https://doi.org/10.29315/gm.873>

### ABSTRACT

Although being relatively uncommon, testicular primary germ cell tumours represent most of testicular tumours in young and middle-aged men. Metastatic disease accounts for up to ten percent of initial presentation.

A 31-year-old man presented with a two-week history worsening left lumbar pain radiating to the ipsilateral lower limb associated with claudication. The straight leg raise test was positive. Therapeutic failure prompted a computed tomography scan, revealing an incidental retroperitoneal mass suspicious of metastatic adenopathy. The patient underwent retroperitoneal mass dissection, followed by right radical orchiectomy. Pathological specimen analysis revealed a burned-out testicular tumour.

Burned-out testicular tumours are a rare entity that may present as extragonadal metastatic germ cell tumours, often targeting the retroperitoneal region, with spontaneous histological regression of the primary testicular lesion. These tumours are usually a challenging diagnosis, emphasizing the importance of physical examination and scrotal ultrasound in the initial approach to these lesions.

**KEYWORDS:** Neoplasms, Germ Cell and Embryonal; Neoplasm Regression, Spontaneous; Retroperitoneal Neoplasms; Testicular Neoplasms

### RESUMO

Embora relativamente incomuns, os tumores primários de células germinativas do testículo representam a maioria dos tumores testiculares em adultos jovens e de meia-idade. A doença metastática representa até 10% das manifestações iniciais destes tumores.

1.Unidade de Saúde Familiar Citânia, Unidade Local de Saúde Tâmega e Sousa, Porto, Portugal. 2. Unidade de Saúde Familiar Torrão, Unidade Local de Saúde Tâmega e Sousa, Porto, Portugal. 3. Unidade de Saúde Familiar Teixeira de Pascoaes, Unidade Local de Saúde Tâmega e Sousa, Porto, Portugal. 4. Department of Pathology, Portuguese Oncology Institute of Porto / Porto Comprehensive Cancer Center Raquel Seruca, Porto, Portugal

Received/Recebido: 2024-01-15. Accepted/Aceite: 2025-11-13. Published online/Publicado online: 2026-01-20. Published/Publicado: 2026-06-09.

© 2025 Gazeta Médica. This is an open-access article under the CC BY-NC 4.0. Re-use permitted under CC BY-NC 4.0. No commercial re-use.

© 2025 Gazeta Médica. Este é um artigo de acesso aberto sob a licença CC BY-NC 4.0. Reutilização permitida de acordo com CC BY-NC 4.0. Nenhuma reutilização comercial.

Homem de 31 anos recorreu à consulta com duas semanas de evolução de lombociatalgia em agravamento e claudicação. O “*straight leg raise test*” era positivo. Por falência terapêutica, foi submetido a tomografia computadorizada, revelando incidentalmente uma massa retroperitoneal, suspeita de adenopatia metastática. O doente foi submetido a dissecação da massa retroperitoneal e, posteriormente, a orquiectomia radical direita. O exame anatomopatológico revelou tumor testicular “*burned-out*”.

Os tumores testiculares “*burned-out*” são uma entidade rara que podem ocorrer como doença metastática extragonadal de tumores de células germinativas, sobretudo na região retroperitoneal, associada a regressão espontânea histológica do tumor testicular primário. O diagnóstico é habitualmente desafiante, pelo que o exame físico e a ecografia escrotal são cruciais na sua abordagem inicial.

**PALAVRAS-CHAVE:** Neoplasias Embrionárias de Células Germinativas; Neoplasias Retroperitoneais; Neoplasias Testiculares; Regressão Neoplásica Espontânea

## INTRODUCTION

Testicular tumours are an uncommon malignancy representing 1% of all adult neoplasms and 5% of urological tumours.<sup>1</sup> Most testicular cancers are germ cell tumours (GCT), which occur in men aged 15–35 years old and account for 90% of all testicular tumours in the histology specimens. Metastatic disease accounts for up to 10% of the initial presentation of these lesions.<sup>2,3</sup>

Some of the recognized risk factors for developing testicular cancer include Klinefelter's syndrome, cryptorchidism, and a known family history of testicular neoplasia.<sup>2</sup>

Burned-out testicular tumour describes a metastatic GCT in extra-gonadal tissues, with spontaneous partial or complete regression of the testicular tumour. Metastases from testicular tumours typically spread predominantly to the lymphatic nodal system, especially those in the retroperitoneal region. Other sites of metastasis include the lungs, liver, bones, and other visceral sites.<sup>4</sup> The primary testicular lesion is not detectable during physical examination and ultrasound findings range from small areas of variable echogenicity, microcalcifications to a completely normal or atrophied testis. Nodal or visceral metastasis represents the clinical manifestations of the disease.<sup>3,5-7</sup> We report a case of a 31-year-old man with a spontaneously regressed primary testicular tumour that presented with involvement of retroperitoneal lymph nodes.

## CASE REPORT

A 31-year-old man presented for consultation with a history of two-week-old worsening left lumbar pain, radiating to the ipsilateral lower limb, causing claudication. The patient reported no other significant complaints, such as paraesthesia or muscle weakness. Physical examination revealed a significant muscle

contracture of the left paraspinal muscles, and a positive straight leg raise test at 40°. There were no other relevant findings. The medical, family, and surgical history were also unremarkable.

The patient was initially medicated with etodolac and a combination of paracetamol with thiocolchicoside. After one week, upon reevaluation and due to persistent pain, diazepam was included in the analgesic regimen. Despite this, the patient showed no response to the prescribed therapy. The worsening pain accompanied by the onset of left lower limb distal paresthesias and muscle weakness, tramadol was associated, and a lumbar computed tomography (CT) scan was requested. CT revealed a suspicious retroperitoneal mass.

The patient was referred to the emergency department for unmanageable pain. Physical exam failed to reveal palpable abdominal mass or lymphadenopathies in the supraclavicular, axillary, or inguinal regions. Abdomino-pelvic CT scan showed a large retroperitoneal contrast-enhancing mass, exhibiting coarse calcifications and both cystic and solid components, involving circumferentially the right ureter, leading to chronic atrophy of the right kidney. The mass exhibited a maximum axial diameter of 10.5 cm (Fig. 1), and it was suspicious for metastatic adenopathy. Other differential diagnoses were also considered, such as sarcoma, lymphoma, or retroperitoneal fibrosis, although these were deemed less likely.

A CT-guided histologic biopsy of the mass was performed; however, the results were inconclusive. Subsequently, the patient underwent an exploratory laparotomy for the excision of the retroperitoneal and pelvic masses and total nephrectomy. The postoperative period was uneventful.

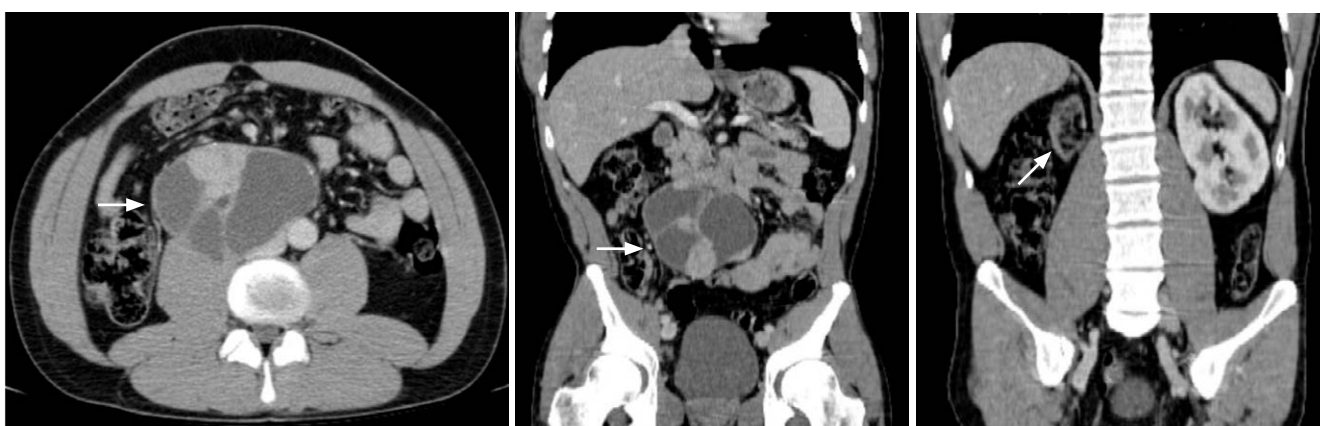Histologic examination of both masses on haematoxylin and eosin (H&E) showed a neoplasm with mul-

ticystic and solid areas. The multicystic component (Fig. 2A) was comprised by fibrous septa of varied thickness, lined by squamous, columnar, and mucinous epithelium. The solid component presented a miscellaneous of architectural patterns, namely glandular and micropapillary (Fig. 2B), solid (Fig. 2C) and trabecular. Immunohistochemistry studies showed positivity for SALL4 (Fig. 2D) and diffuse positivity for cytokeratins AE1/AE3 (Fig. 2E) and Cam5.2, and, in the absence of expression of WT1, PAX8, chromogranin A, SOX10, PS100, TTF1, CDX2, HepPar1, GATA3, PSA, SMA and desmin.<sup>8</sup> Based on these findings, a diagnosis of GCT with characteristics of teratoma and somatic-type malignancy in the form of carcinoma was favoured. The surgery was a R0 resection, with no residual lesions.

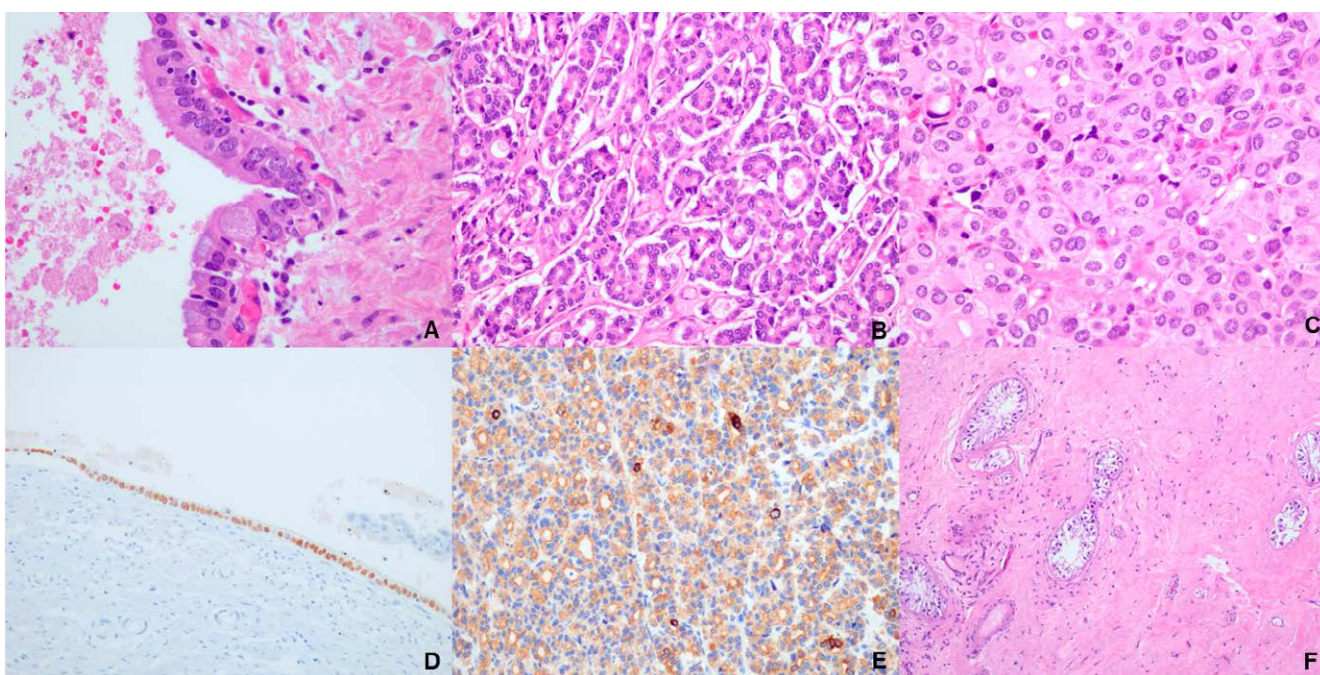
In view of these findings, the patient was referred to the urologic consultation and reported no history of cryptorchidism, testicular pain, or noticeable masses. A careful physical examination of the scrotum was carried out and no masses or nodules were palpable bilaterally, although the right testicle had a slightly larger volume and rougher consistency.

Testicular tumour markers revealed a normal serum levels  $\beta$ -human chorionic gonadotropin ( $\beta$ -HCG) ( $< 0.2$  IU/L), serum lactate dehydrogenase (176 ng/mL) and  $\alpha$ -fetoprotein (AFP) (0.9 ng/mL).

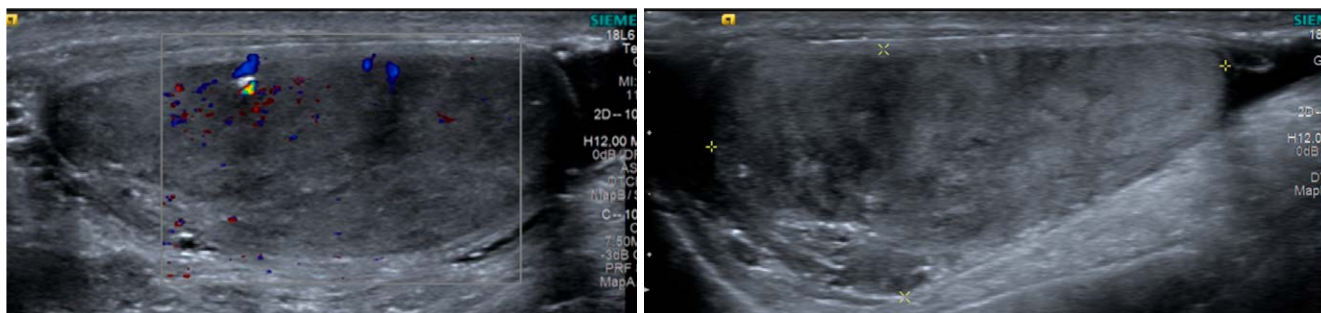
Scrotal ultrasound revealed scattered microcalcifications and scar tissue on the right testicle, without distinct testicular masses or nodules suspected of malignancy (Fig. 3).



**FIGURE 1.** Axial and coronal contrast-enhanced abdominal and pelvic CT scan showed a large complex cystic and solid retroperitoneal mass on the right side of the aorta (arrowheads). This lesion involves the right ureter with consequent right kidney atrophy (arrow).



**FIGURE 2.** Retroperitoneal mass. A) H&E, 40x. Cystic areas covered by glandular epithelium showing goblet cells B) H&E, 20x. Glandular and micropapillary pattern. C) H&E, 40x. Solid pattern, showing atypical cells with oval and vesicular nuclei, with fine chromatin, inconspicuous nucleoli and moderate, eosinophilic and slightly granular cytoplasm. D) IHC, 20x. SALL4 focally positive on cystic component. E) IHC, 20x. Cytokeratin AE1/3 positive. Orchidectomy specimen. F) H&E, 20x. Extensive hyalinized fibrosis with mild lymphoplasmacytic infiltrate and increased of small blood vessels, surrounding residual seminiferous tubules.



**FIGURE 3.** Ultrasound of the right testicle showed diffuse heterogeneous echotexture and scattered microcalcifications. There are no distinct testicular masses or nodules suspected of malignancy.

Right radical inguinal orchiectomy was performed, with the insertion of a scrotal prosthesis. The histologic analysis of the removed testicular tissue revealed areas of fibrotic scarring, with no viable seminoma or non-seminomatous elements (Fig. 2F). These findings were consistent with the diagnosis of spontaneous regression of a GCT, also known as burned-out GCT.

## DISCUSSION

Burned-out testicular tumours are a rare occurrence, usually presenting a challenging diagnosis. Seminoma, a germ cells tumour subtype, is the most common histological type of testicular tumour associated with a burned-out testicular tumour, followed by embryonal carcinoma.<sup>3,9</sup> Careful physical examination and scrotal ultrasonography of both testes are essential for identifying the primary lesion site and detecting the regressed tumour. Furthermore, a thorough assessment of the abdomen, cervical, axillary, and supraclavicular areas, along with an evaluation for gynecomastia, is crucial for an accurate management.

In individuals with seminoma GCT, serum tumour markers demonstrate low sensitivity, often displaying a mostly normal range. Serum  $\beta$ -HCG levels may be either elevated in seminoma or non-seminoma GCT, and elevated serum AFP levels raise suspicion for non-seminomatous GCT. Elevated tumour markers, in the presence of a normal testicular exam with retroperitoneal adenopathy, may be sufficient for the diagnosis of burn-out GCT.<sup>3,10</sup> In this reported case, tumour markers were within normal values, as expected, since the tumour markers were only requested after the RO retroperitoneal mass excision, and the primary testicular tumour was no longer viable.

Primary retroperitoneal GCT exhibit a more aggressive nature compared to primary testicular GCT. Accurate discrimination between primary retroperitoneal GCT from burned-out testicular tumours is crucial, since treatment options differ substantially, due to the na-

ture of primary retroperitoneal GCT being more resistant to chemotherapeutic agents.<sup>11</sup>

Treatment of a burn-out primary testicular tumour requires orchidectomy with or without adjuvant chemotherapy and/or radiation. Despite its aggressiveness, primary testicular GCT have an excellent prognosis, being associated with high cure rates, with an overall long-term survival of 97%, regardless of the stage of the disease. Proper surveillance requires regular clinical evaluation, measurement of serum tumour markers and cross-sectional imaging to early identify patients who might have a relapse.<sup>4,12</sup>

Retroperitoneal masses may be evident through diverse presentations, including low back pain, abdominal discomfort, or enlargement of the abdominal perimeter. In case of persistent lumbar pain for several weeks, organic cause should be suspected, warranting further evaluation. This case report emphasizes the potential for burned-out testicular tumours to present with a retroperitoneal mass in middle-aged males. Consequently, when a retroperitoneal mass is identified in a young man, it is crucial to carefully evaluate both testicles. Despite a normal physical examination of the scrotum, and ultrasound should be performed.

## CONTRIBUTORSHIP STATEMENT/ DECLARAÇÃO DE CONTRIBUIÇÃO

NSS, DSS - Conceptualisation, literature review and article writing

RM, AC - Article writing

MA, SCM - Article writing, review and supervision

All the authors approved the final version to be published

NSS, DSS - Conceptualização, revisão da literatura e redação do artigo

RM, AC - Redação do artigo

MA, SCM - Redação, revisão e supervisão do artigo

Todos os autores aprovaram a versão final a ser publicada

## ETHICAL DISCLOSURES

**CONFLICTS OF INTEREST:** The authors have no conflicts of interest to declare.

**FINANCING SUPPORT:** This work has not received any contribution, grant or scholarship.

**CONFIDENTIALITY OF DATA:** The authors declare that they have followed the protocols of their work center on the publication of patient data.

**PATIENT CONSENT:** Consent for publication was obtained.

**PROVENANCE AND PEER REVIEW:** Not commissioned; externally peer-reviewed

## RESPONSABILIDADES ÉTICAS

**CONFLITOS DE INTERESSE:** Os autores declaram a inexistência de conflitos de interesse na realização do presente trabalho

**FONTES DE FINANCIAMENTO:** Não existiram fontes externas de financiamento para a realização deste artigo.

**CONFIDENCIALIDADE DOS DADOS:** Os autores declaram ter seguido os protocolos da sua instituição acerca da publicação dos dados de doentes.

**CONSENTIMENTO:** Consentimento do doente para publicação obtido.

**PROVENIÊNCIA E REVISÃO POR PARES:** Não comissionado; revisão externa por pares.

## REFERENCES

1. Park JS, Kim J, Elghiaty A, Ham WS. Recent global trends in testicular cancer incidence and mortality. *Medicine* 2018;97:e12390. doi: 10.1097/MD.00000000000012390
2. Bosl GJ, Motzer RJ. Testicular germ cell cancer. *N Engl J of Med.* 1997; 337:242-54. doi: 10.1056/NEJM199707243370406
3. Samnani S, Alimohamed N. Case - "Burned-out" testicular tumour: A rare entity with diagnostic dilemma. *Can Urol Assoc J.* 2022;16:E572-E574. doi: 10.5489/cuaj.7879.
4. Patrikidou A, Cazzaniga W, Berney D, Boormans J, de Angst I, Di Nardo D, et al. European Association of Urology Guidelines on Testicular Cancer: 2023 Update. *Eur Urol.* 2023;84:289-301. doi: 10.1016/j.eururo.2023.04.010.
5. Persano G, Crocoli A, De Pasquale MD, Cozza R, Alaggio R, Diomedi Camassei F, et al. Burned-Out Testicular Tumors in Adolescents: Clinical Aspects and Outcome. *Front Pediatr.* 2021;9:688021. doi: 10.3389/fped.2021.688021.
6. Budak S, Celik O, Turk H, Suelozgen T, Ilbey YO. Extragonadal germ cell tumor with the "burned-out" phenomenon presented a multiple retroperitoneal masses: a case report. *Asian J Androl.* 2015;17:163-4. doi: 10.4103/1008-682X.137481.
7. Katabathina VS, Vargas-Zapata D, Monge RA, Nazarullah A, Ganeshan D, Tammisetti V, et al. Testicular Germ Cell Tumors: Classification, Pathologic Features, Imaging Findings, and Management. *Radiographics.* 2021;41:1698-1716. doi: 10.1148/rg.2021210024.
8. Tateo V, Mollica V, Rizzo A, Santoni M, Massari F. Re: WHO Classification of Tumours, 5th Edition, Volume 8: Urinary and Male Genital Tumours. *Eur Urol.* 2023;84:348-349. doi: 10.1016/j.eururo.2023.04.030.
9. Mosillo C, Scagnoli S, Pomati G, et al. Burned-out testicular cancer: Really a different history. *Case Rep Oncol.* 2017; 10:846-50. doi: 10.1159/000480493.
10. Oldenburg J, Berney DM, Bokemeyer C, Climent MA, Daugaard G, Gietema JA, et al. Testicular seminoma and non-seminoma: ESMO-EURACAN Clinical Practice Guideline for diagnosis, treatment and follow-up. *Ann Oncol.* 2022;33:362-75. doi: 10.1016/j.annonc.2022.01.002.
11. Balalaa N, Selman M, Hassen W. Burned-out testicular tumour: a case report. *Case Rep Oncol.* 2011; 4:12-5. doi: 10.1159/000324041.
12. Rajpert-De Meyts E, McGlynn KA, Okamoto K, Jewett MA, Bokemeyer C. Testicular germ cell tumours. *Lancet.* 2016;387:1762-74. doi: 10.1016/S0140-6736(15)00991-5.